

General Hospital – Sample Pain Note

Patient Name: T Jackson
Procedure Date: 1/03/2008 07:40:00
Date of Birth: 12/26/1972
Account #: 122672

Gender: F
MRN: 6516905681
Age: 35
Note Status: Finalized

Surgical Staff: John H. White, MD
Referring MD: Jennifer Jones, MD
Procedure:

Left L3-L4 Transforaminal Epidural Steroid Injection (L3 Nerve Root) and Left L4-L5 Transforaminal Epidural Steroid Injection (L4 Nerve Root) under Fluoroscopic Guidance

Patient Profile:

This is a 44 year old female. The patient reports greatly increasing pain over the past several weeks. In addition, the patient has associated radicular symptoms of aching, radiating to the L3 dermatome distribution and L4 dermatome distribution. She is status post posterior fusion and lumbar decompression within the past several years. Due to the nature of the patient's persistent pain, epidural steroid injection is recommended. The alternatives, benefits, and risks were discussed with the patient. The patient verbalized understanding of the risks as well as the alternatives and wished to proceed with the procedure. A signed and witnessed informed consent was placed on the chart.

Pre-OP Diagnosis:

Left leg pain, Left leg weakness, Left L3-4 radicular pain, Left L4-5 radicular pain, Lumbar spondylosis

Post-OP Diagnosis:

Left leg pain, Left leg weakness, Left L3-4 radicular pain, Left, L4-5 radicular pain, Lumbar spondylosis

Anesthesia:

Midazolam 2 mg IV
 Fentanyl 50 mcg IV

Description of Procedure:

Patient Positioning:

- The patient was placed in the prone position on the radiolucent operating table.

Description of Method:

- The lumbar area was prepped and draped in the appropriate sterile fashion. The left L3-L4 level was identified for a transforaminal epidural injection and the overlying skin and subcutaneous tissue were anesthetized. A 22 gauge 3.5 inch B-bevel spinal needle was passed through the skin wheal and advanced in a ventral direction until the tip of the needle was properly placed in the left superior posterior intervertebral foramen as confirmed by AP and lateral fluoroscopic views. No blood was aspirated. There was no CSF flow. Following negative aspiration, 1 mL Isovue-M200 was injected to produce the epidurogram. There was appropriate needle placement and no intravascular or intrathecal flow. 1 mL of a 40 mg/mL solution of Kenalog and 1 mL of 1% Lidocaine was injected.

- Attention was then turned to the next injection. The lumbar area was prepped and draped in the appropriate sterile fashion. The left L4-L5 level was identified for a transforaminal epidural injection and a skin wheal was made at the spinal needle entry site. A 22 gauge 3.5 inch spinal needle was passed through the skin wheal and advanced in a ventral direction until the tip of the needle was properly placed in the left superior posterior intervertebral foramen as confirmed by AP and lateral fluoroscopic views. No blood was aspirated. There was no CSF flow. Following negative aspiration 1 mL Isovue-M200 was injected to produce the epidurogram. There was appropriate needle placement and no intravascular or intrathecal flow. 1 mL of a 40 mg/mL solution of Kenalog and 1 mL of 1% Lidocaine was injected. The patient tolerated the procedure well.

Drains / Dressing:

- Applied sterile dressing including BAND-AID.

Patient to Recovery Room:

-The patient tolerated the procedure well, and was brought to the recovery room in excellent condition.

Complications:

No immediate complications

Post-Op Plan:

DISCHARGE ORDERS:

- Disposition:

- Discharge patient to home today.

- Activity:

- Patient may resume normal activity level in 1 day.

- Follow-up:

- Pain clinic in 2 weeks

Patient Name: T Jackson
Procedure Date: 1/03/2008 07:40:00
Date of Birth: 12/26/1972
Account #: 122672

Gender: F
MRN: 6516905681
Age: 35
Note Status: Finalized

CPT4© Code(s):

64483, LT, Injection, anesthetic agent and/or steroid, transforaminal epidural; lumbar or sacral, single level
 64484, LT, Injection, anesthetic agent and/or steroid, transforaminal epidural; lumbar or sacral, each additional level (List separately in addition to code for primary procedure)
 77003, Fluoroscopic guidance and localization of needle or catheter tip for spine or paraspinous diagnostic or therapeutic injection procedures (epidural, transforaminal epidural, subarachnoid, paravertebral facet joint, paravertebral facet joint nerve or sacroiliac joint), including neurolytic agent destruction

ICD9 Code(s):

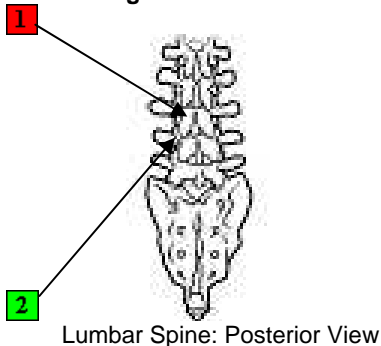
724.4, Thoracic or lumbosacral neuritis or radiculitis
 721.3, Lumbosacral spondylosis without myelopathy
 729.5, Pain in limb
 729.89, Other musculoskeletal symptoms referable to limbs

CPT Copyright 2007 American Medical Association.

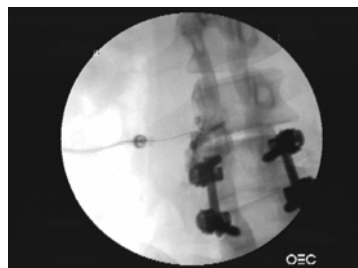No fee schedules, basic units, relative values or related listings are included in CPT. AMA does not directly or indirectly practice medicine or dispense medical services. AMA assumes no liability for data contained or not contained herein.

CPT is a registered trademark of the American Medical Association.

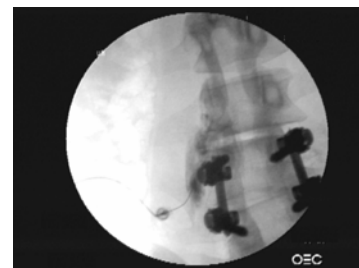Procedure Images:



Lumbar Spine: Posterior View



1 L-3



2 Foramen

www.provationmedical.com

E-signed by John H. White, MD

John H. White, MD
 Signed Date: 01/03/2008 07:59:00
 Number of Addenda: 0
 Note generated on: 01/03/2008

Printed: Jan. 2008. Codes subject to change based on quarterly/annual CPT/ICD/CCI changes
 © 2008 ProVation Medical, Inc. All Rights Reserved

samplepain-06