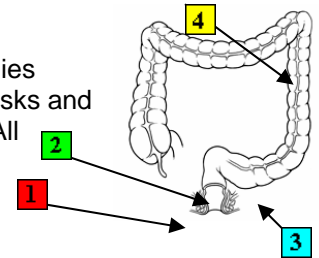


**General Hospital – Sample GI Note**

**Patient Name:** Mabel Davis  
**Procedure Date:** 01/02/2008 10:35:00  
**Date of Birth:** 12/26/1972  
**Admit Type:** Outpatient  
**Note Status:** Finalized

**Gender:** F  
**MRN:** 084985  
**Age:** 35  
**Account #:** 568945  
**Attending MD:** John H. White

**Procedure:** Colonoscopy  
**Indications:** Hematochezia, Personal history of colonic polyps  
**Providers:** John H. White MD, Kevin P. Taylor MD (Fellow)  
**Referring MD:** William Jones, MD  
**Medications:** Midazolam 2 mg IV, Fentanyl 100 mcg IV  
**Procedure:**



Patient identification and proposed procedure were verified by physician and the nurse in the pre-procedure area. A History and Physical has been performed, and patient medication allergies have been reviewed. The patient's tolerance of previous anesthesia has been reviewed. The risks and benefits of the procedure and the sedation options and risks were discussed with the patient. All questions were answered and informed consent was obtained. Mental Status Examination: alert and oriented. Airway Examination: normal oropharyngeal airway and neck mobility. Respiratory Examination: clear to auscultation. CV Examination: RRR, no murmurs, no S3 or S4. ASA Grade Assessment: P1 A normal healthy patient. After reviewing the risks and benefits, the patient was deemed in satisfactory condition to undergo the procedure. The anesthesia plan was to use moderate sedation/analgesia (conscious sedation). Immediately prior to administration of medications, the patient was re-assessed for adequacy to receive sedatives. The heart rate, respiratory rate, oxygen saturations, blood pressure, adequacy of pulmonary ventilation, and response to care were monitored throughout the procedure. The physical status of the patient was re-assessed after the procedure. After I obtained informed consent, the scope was passed under direct vision.

Throughout the procedure, the patient's blood pressure, pulse, and oxygen saturations were monitored continuously. The colonoscope was introduced through the anus and advanced to the cecum, identified by appendiceal orifice & IC valve. The quality of the prep was good. The patient tolerated the procedure well.

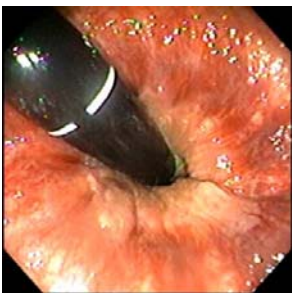
**Findings:**

A sessile, non-bleeding polyp was found in the rectum. The polyp was 5 mm in size. The polyp was removed with a saline injection-lift technique using the hot snare. Resection and retrieval were complete. Estimated blood loss was minimal.

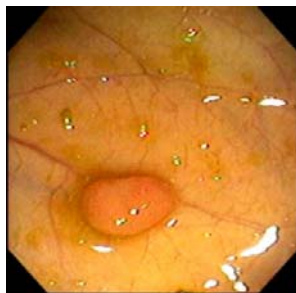A pedunculated, non-bleeding polyp was found in the sigmoid colon. The polyp was 7 mm in size. The polyp was removed with a hot forceps. Resection and retrieval were complete. Estimated blood loss was minimal.

Multiple large-mouthed diverticula were found in the descending colon.

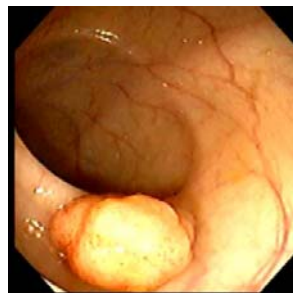
Internal, non-bleeding, prolapsed with spontaneous reduction (grade II) hemorrhoids were found on retroflexion.



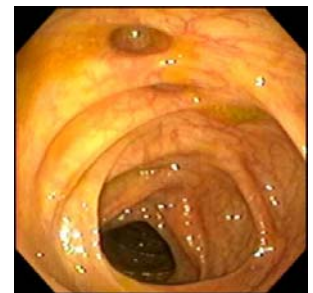**1** Rectum/Hemorrhoids



**2** Rectum/Polyp



**3** Sigmoid Colon/Polyp



**4** Descending Colon/Diverticula

**Patient Name:** Mabel Davis  
**Procedure Date:** 01/02/2008 10:35:00  
**Date of Birth:** 12/26/1972  
**Admit Type:** Outpatient  
**Note Status:** Finalized

**Gender:** F  
**MRN:** 084985  
**Age:** 35  
**Account #:** 568945  
**Attending MD:** John H. White

**Impression:**

- One 5 mm benign appearing polyp in the rectum. Resected and retrieved.
- One 7 mm polyp in the sigmoid colon. Resected and retrieved.
- Diverticulosis of the descending colon.
- Internal hemorrhoids were found.

**Recommendation:**

- High fiber diet.
- Await pathology results.
- Repeat colonoscopy for surveillance in 3 years.
- The findings and recommendations were discussed with the patient.

**CPT® Code(s):**

- 45385, Colonoscopy, flexible, proximal to splenic flexure; with removal of tumor(s), polyp(s), or other lesion(s) by snare technique
- 45384, 59, Colonoscopy, flexible, proximal to splenic flexure; with removal of tumor(s), polyp(s), or other lesion(s) by hot biopsy forceps or bipolar cautery
- 45381, Colonoscopy, flexible, proximal to splenic flexure; with directed submucosal injection(s), any substance

**ICD Code(s):**

- 211.4, Benign neoplasm of rectum and anal canal
- 211.3, Benign neoplasm of colon
- 562.10, Diverticulosis of colon (without mention of hemorrhage)
- 455.2, Internal hemorrhoids with other complication
- 578.1, Blood in stool

**CPT Copyright 2007 American Medical Association.**

*No fee schedules, basic units, relative values or related listings are included in CPT. AMA does not directly or indirectly practice medicine or dispense medical services. AMA assumes no liability for data contained or not contained herein.*

*CPT is a registered trademark of the American Medical Association.*

E-signed by John H. White, MD

John H. White, MD  
Signed Date: 01/02/2008 11:35:05  
Number of Addenda: 0  
Note generated on: 1/02/2008

E-signed by Kevin P. Taylor, MD

Kevin P. Taylor, MD  
Signed Date: 01/02/2008 11:35:05

[www.provationmedical.com](http://www.provationmedical.com)

Printed Jan 2008. Codes subject to change based on quarterly/annual CPT/ICD/CCI changes.  
© 2008 ProVation Medical, Inc. All Rights Reserved.

samplegi06