

General Hospital – Sample Urology Note

Patient Name: David Davis
MRN: 084985
Date of Birth: 1/18/1939
Age: 72
Gender: M

Procedure Date: 1/26/2011
Attending MD: Keith Kaye, MD
Account #: 00545418
Admit Type: Outpatient
Note Status: Finalized

Surgical Staff: Keith W. Kaye MD (Surgeon)
Referring MD: Jon Gulliver, MD

Procedure:

Medium (2.0 - 5.0 cm) Transurethral Bladder Tumor Resection
- Random Biopsy(ies) Taken

Patient Profile

This is a 70-year-old male.

The Following Most Recent, Available Investigations were Reviewed and Found to be Abnormal:

- Urine Cytology.

The Following Most Recent, Available Investigations were Reviewed and Found to be Normal:

- Intravenous Pyelogram.

Pre-OP Dx:

Lateral Wall Bladder Transitional Cell Carcinoma

Post-OP Dx:

Lateral Wall Bladder Transitional Cell Carcinoma, Awaiting Final Pathology

Anesthesia:

General

Findings:

Normal Ureteral Orifices Bilaterally

Single Medium-sized Papillary Bladder Tumor/Mass - 3 cm in Diameter, Right Lateral Wall

Erythematous (Hyperemic) Bladder Mucosa, Left Lateral Wall

Trilobar Prostatic Hypertrophy with Mild Intravesical Extension

Description of Procedure:

Informed Consent:

- Risks and Benefits of Procedure and Alternatives Discussed with Patient and Informed Consent Obtained

Patient Position:

- Dorsal Lithotomy

Prep and Drape:

- Patient Prepped and Draped in Usual Sterile Fashion using Betadine

Instruments:

- Standard 24 Fr Resectoscope

Special Aspects of Procedure:

- Specimens Removed from Right Bladder Wall

- Tumor Resection was Complete

- At Completion of Procedure Deep Biopsy(ies) Taken from Resected Area

- Other Biopsy(ies) Taken from Left Bladder Wall, Anterior Bladder Wall, Posterior Bladder Wall, Bladder Neck and Urethra

Urinary Catheter:

- 18 Fr Foley Catheter with 5 cc Balloon

EBL: Minimal

Complications:

No immediate complications

Post-OP Orders:

- Recovery Room Orders Per Standing Orders

Patient Name: David Davis
MRN: 084985
Date of Birth: 1/18/1939
Age: 72
Gender: M

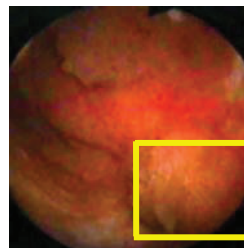
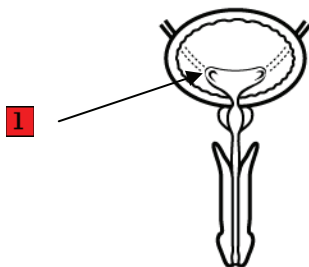
Procedure Date: 1/26/2011
Attending MD: Keith Kaye, MD
Account #: 00545418
Admit Type: Outpatient
Note Status: Finalized

Patient Instructions:

Patient Discharge Instructions:

- Diet:
 - Resume Regular Diet
- Medications:
 - Tylenol #3. 1-2 Tablets Orally every 4-6 Hours as Necessary
 - Ciprofloxacin (Cipro) 500 mg Twice Daily for 2 Days
- Activity:
 - No Restrictions: As Tolerated
 - May Return to Work in 2 Days
- Special Instructions:
 - No Aspirin / Aspirin Like Products such as Bufferin, Advil, Motrin, Alka-Seltzer, Ibuprofen for 5 Days
 - You May Take Medications with Acetaminophen such as Tylenol
 - No Blood Thinners, like Coumadin for 5 Days
- Call If:
 - Dizziness, Fainting or Blackout Spells, Temperature > 101 °F, Increasing Blood in Urine and Inability To Void
 - Follow-Up Appointments to be Scheduled by Patient

Procedure Images:



1 Bladder

CPT4© Code(s):

52235, Cystourethroscopy, with fulguration (including cryosurgery or laser surgery) and/or resection of MEDIUM bladder tumor(s) (2.0 to 5.0 cm)
 52204, 59, Cystourethroscopy, with biopsy

ICD9 Code(s):

188.2, Malignant neoplasm of lateral wall of urinary bladder

CPT © 2010 American Medical Association. All Rights Reserved.

E-signed by, Keith W. Kaye, MD

Keith W. Kaye, MD

Signed Date: 1/26/2011 11:18:48

Number of Addenda: 0

Note generated on: 1/26/2011 11:18:48 am