

## General Hospital – Sample General Surgery Note

**Patient Name:** Mike Jones  
**Account #:** 659863  
**Age:** 51  
**Note Status:** Finalized  
**Attending MD:** Edward Smith

**MRN:** 065273  
**Date of Birth:** 1/9/1960  
**Gender:** M  
**Procedure Date:** 11/21/2011

**Surgical Staff:** Edward Smith, MD (Surgeon)

**Referring MD:** James Martin, MD

**Procedure:**

Laparoscopic Cholecystectomy

**Patient Profile:**

This is a 51-year-old male patient. Patient has symptoms of abdominal pain and fatty food intolerance over the past month. Refer to note in patient chart for documentation of history and physical. An ultrasound of the gallbladder showed multiple gallbladder stones. Due to the nature of the patient's progressive symptoms, laparoscopic cholecystectomy is recommended. The alternatives, risks and benefits of surgery were discussed with the patient. The patient verbalized understanding of the risks as well as the alternatives to surgery. The patient wished to proceed with operative intervention. A signed and witnessed informed consent was placed on the chart.

**Pre-OP Diagnosis:**

Chronic right upper quadrant and epigastric abdominal pain.  
 Cholelithiasis with chronic cholecystitis.

**Post-OP Diagnosis:**

Chronic right upper quadrant and epigastric abdominal pain.  
 Cholelithiasis with chronic cholecystitis.

**Anesthesia:**

General - Endotracheal

**Findings:**

Gallbladder:  
 - Thickened gallbladder wall.  
 - Acute and chronic inflammation.  
 - Multiple multifaceted green gallstones were seen.

**Description of Procedure:**

Preoperative Medications / Therapy:  
 - Ampicillin Sulbactam (Unasyn) 3 gm IV given prior to incision.  
 - Knee high pneumatic compression stockings.

Abdominal Prep and Drape:

- The patient was placed on the standard operating table in the supine surgical position and sites of compression were well padded. An OG tube was placed orally. The patient was sterilely prepped with betadine and draped in the usual fashion.

Laparoscope Insertion and Accessory Port Placement:

- A 10 mL solution of 0.5% Bupivacaine with epinephrine was infiltrated into the proposed incision site. A small infraumbilical area puncture incision was made in the skin and was carried down through the subcutaneous tissue to the fascia. Bleeding was controlled with electrocautery. An incision was made in the fascia and the peritoneum and 0 Vicryl stay sutures were placed on both sides of the fascial incision. A 10/12 mm Hasson cannula was inserted through the opening into the peritoneal cavity and was fixed into place by the fascial stay sutures. The peritoneal cavity was then insufflated with CO2 to a pressure of 14 mmHg.  
 - A 0 degree, 10 mm laparoscope was inserted through the port into the peritoneal cavity. Initial exploration of the peritoneal cavity revealed no evidence of bowel injury or bleeding.  
 - Local anesthetic was infiltrated into the tissues at the proposed accessory port sites. Using small puncture incisions, one 10 mm port was placed in the subxiphoid area and two 5mm ports were placed in the right subcostal midclavicular line and right subcostal anterior axillary line under laparoscopic vision.

Procedure Details:

- The liver was examined and appeared smooth. The gallbladder was visualized and was found to be inflamed and thickened with filmy adhesions present. The adhesions to the gallbladder were taken down with sharp dissection. The gallbladder was decompressed by aspirating the contents using a 5 mm needle aspirating sound. The patient was then positioned in a reverse Trendelenburg position and rotated to the left. The fundus of the gallbladder and right lobe of the liver were elevated superiorly. The infundibulum of the gallbladder was retracted anteriorly. The cystic duct-gallbladder junction was then carefully isolated with blunt dissection and the cystic duct, cystic artery and gallbladder neck were identified. The cystic duct was then milked distally toward the gallbladder to clear the duct of stones or stone fragments. The cystic duct was then occluded with two 5mm clips proximally and one clip distally using a 5 mm clip applier and was then divided. The cystic artery was then occluded with two 5 mm clips proximally and one clip distally and was then divided. The gallbladder was then dissected free from the liver bed using L hook electrocautery. Prior to complete detachment of the gallbladder from the liver, the area was carefully inspected and clips on the cystic duct and cystic artery were intact, no bleeding was present and no bile leakage was present. The gallbladder specimen was placed into the endoscopic specimen bag and withdrawn through the incision.  
 - Prior to closure, the peritoneal cavity was examined and evaluation showed complete hemostasis, no bleeding from the gallbladder bed and no bile leak.

**Patient Name:** Mike Jones  
**Account #:** 659863  
**Age:** 51  
**Note Status:** Finalized  
**Attending MD:** Edward Smith

**MRN:** 065273  
**Date of Birth:** 1/9/1960  
**Gender:** M  
**Procedure Date:** 11/21/2011

**Pathology Specimen:**

- Gallbladder sent for routine pathology.

**Port Trocar and Scope Removal:**

- The instruments and accessory port trocars were then removed under laparoscopic visualization and there was no evidence of bleeding. The pneumoperitoneum was released and the laparoscope and the primary port trocar were then removed.

**Port Closure Abdomen:**

- The primary and subxiphoid ports were closed. The fascia was closed with #0 Vicryl using interrupted technique. The skin was closed with 4-0 Vicryl using interrupted subcuticular technique.

**Dressing:**

- A sterile dressing was applied to the port sites using Band-Aid and Steri-Strip closures.

**Sponge / Instrument / Needle Counts:**

- Final counts were correct.

**EBL:**

- Estimated blood loss: 10 mL

**Patient to Recovery Room:**

- The patient tolerated the procedure well, and was brought to the recovery room in stable condition. The procedure results were discussed with the patient and the patient's wife.

**Complications:**

None

**CPT® Code(s):**

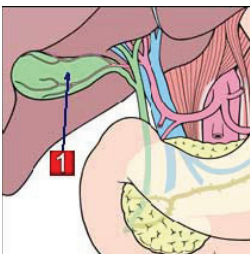
47562, Laparoscopy, surgical; cholecystectomy

**ICD Code(s):**

574.10, Calculus of gallbladder with other cholecystitis, without mention of obstruction.

CPT © 2010 American Medical Association. All Rights Reserved.

**Procedure Images:**



**E-signed by: Edward Smith, M.D.**

Edward Smith, M.D.

Signed Date: 11/21/2011 11:27:07

Number of Addenda: 0

This report has been signed electronically.

Note initiated on 11/21/2011 11:10:00



**1** Gall Bladder

Printed 2011. Codes subject to change based on quarterly/annual CPT/ICD/CCI changes.