

## GYN – Sample Diagnostic Laparoscopy Note

**Patient Name:** Jane Jones  
**MRN:** 4555  
**Note Status:** Finalized

**Procedure Date:** 01/30/2011 10:00:00  
**Account #:** 22233  
**Attending MD:** Patrick B. Johnson, MD

---

**Providers:**

Patrick B. Johnson, MD (Doctor)

**Referring MD:**

David Whalen, MD

**Procedure:**

Diagnostic Laparoscopy with Right Ovary Biopsy

---

**Procedure:**

Diagnostic Laparoscopy  
Laparoscopic Right Ovarian Biopsy  
Cauterization of Pelvic Endometriosis by Laparoscopy

**Pre-OP Diagnosis:**

Pelvic pain, Dysmenorrhea

**Post-OP Diagnosis:**

Endometriosis of right ovary, Right ovarian fossa endometriosis, Right uterosacral ligament endometriosis

**Anesthesia:**

General Anesthesia via Endotracheal Intubation

**Findings:**

Endometriosis - AFS Stage II.  
Moderate gun powder endometriosis implants involving the right ovary, right ovarian fossa and right uterosacral ligament.

**Description of Procedure:**

--- Diagnostic Laparoscopy ---

Preoperative Medications / Therapy:

- Toradol 30 mg IV given prior to induction.

Prep and Drape:

- The patient was placed on the standard operating table in the dorsal lithotomy surgical position and was placed in Allen stirrups. The patient was sterilely prepped with povidone iodine solution (Betadine) and draped in the usual fashion.

Laparoscope Insertion and Accessory Port Placement:

- A 2 mL solution of 1% Lidocaine with epinephrine was infiltrated into the proposed incision site. A small skin nick puncture incision was made in the skin in the infraumbilical area and carried down through the subcutaneous tissue. The Veress needle was inserted into the puncture wound and was advanced into the peritoneal cavity directing it toward the pelvis. Aspiration from the Veress needle into an attached syringe was as expected. Intraperitoneal placement was confirmed by hanging drop test. Intraperitoneal placement was good. The peritoneal cavity was then insufflated with 3.5 liters of CO<sub>2</sub> to a pressure of 14 mmHg. A 10 mm reusable trocar was inserted into the peritoneal cavity through an infraumbilical area stab incision and the CO<sub>2</sub> gas line was attached to the primary trocar port.

- A 0 degree, 10 mm laparoscope was inserted through the port into the peritoneal cavity.

- Accessory port(s) were then placed for instrumentation and visualization. Local anesthetic was infiltrated into the skin. A 5 mm port was placed in the suprapubic area and a 3 mm port was placed in the right lower quadrant under laparoscopic vision.

Procedure Details:

- Intra-abdominal exploration revealed normal left tubo-ovarian structures, uterus and cul de sac and adhesions and endometriosis involving the right tubo-ovarian structures.

- Prior to closure, the peritoneal cavity was examined and evaluation showed adequate hemostasis.

--- Laparoscopic Biopsy ---

Procedure Details:

- The adhesions between the right ovary and fossa were bluntly lysed and an endometrial implant on the right ovary was biopsied.

--- Laparoscopic Endometriosis Treatment ---

Procedure Details:

- Endometrial implants on the right ovary in the right ovarian fossa and along the right uterosacral ligament were cauterized using needle tip monopolar cautery.

**Patient Name:** Jane Jones  
**MRN:** 4555  
**Note Status:** Finalized

**Procedure Date:** 01/30/2011 10:00:00  
**Account #:** 22233  
**Attending MD:** Patrick B. Johnson, MD

**Pathology Specimen:**

- Tissue from the right ovary was sent in saline for routine pathology.

**Dressing:**

- Incisions were dressed with Steri-Strips.

**EBL:**

- Estimated blood loss: Minimal

**Patient to Recovery Room:**

- The patient tolerated the procedure well and was brought to the recovery room in excellent condition. The procedure results were discussed with the patient.

**Complications:**

None.

**CPT Codes:**

58662, Laparoscopy, surgical; with fulguration or excision of lesions of the ovary, pelvic viscera, or peritoneal surface by any method

49321, Laparoscopy, surgical; with biopsy (single or multiple)

**ICD-9-CM codes:**

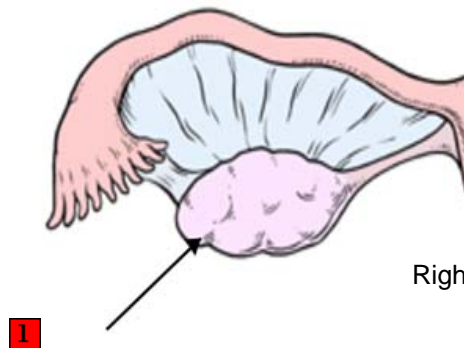
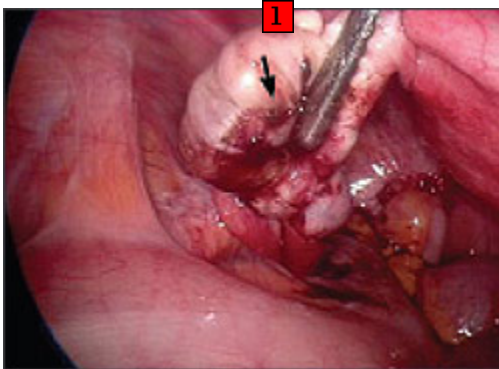
617.3, Endometriosis of pelvic peritoneum

617.1, Endometriosis of ovary

625.3, Dysmenorrhea

625.9, Unspecified symptom associated with female genital organs

**CPT © 2010 American Medical Association. All Rights Reserved.**



Right ovary endometriosis

E-Signed by: Patrick B. Johnson

Patrick B. Johnson, MD

Signed Date: 01/30/2011 10:35:08

Number of Addenda: 0

This report has been signed electronically.

Note initiated on 1/30/2011 10:00:00

Printed 2011. Codes subject to change based on quarterly/annual CPT/ICD/CCI changes.