

## General Hospital – Sample Echocardiogram Note

**Patient Name:** Wilson Jackson  
**Procedure Date:** 02/06/2011 14:05:00  
**Date of Birth:** 12/19/1962  
**Admit Type:** Outpatient  
**Note Status:** Finalized

**Gender:** M  
**MRN:** 562525256  
**Age:** 48  
**Account #:** 998877456215  
**Attending MD:** Tyrone X. Smith MD

**Providers:**

Tyrone X. Smith, MD (Doctor)

**Procedure:**

Complete Echocardiogram: 2-Dimensional, M-mode with Complete Doppler and Color Flow Imaging

**Indications:**

Congestive heart failure.

**Adequacy/Tolerance:**

The quality of the study was adequate.

**Findings:**

Overview: Transthoracic imaging of the cardiac structures was performed using 2D, M-mode, Color flow and spectral Doppler imaging. The patient's heart rate, rhythm and blood pressure are normal. Baseline blood pressure is 122 / 78 mmHg.

**Left Ventricle:** The ejection fraction is 30%. The left ventricular chamber is moderately dilated. Mild left ventricular concentric hypertrophy is present. The mid, basilar and apical segments of the inferior wall are severely hypokinetic.

The remaining left ventricular segments are normal.

**Mitral Valve:** Mild mitral regurgitation is noted by color Doppler. There is mitral annular calcification with no thickening of the mitral leaflets. Mild regurgitation is present.

**Aortic Valve:** Findings suggest mild aortic valvular stenosis. The aortic valve measures 1.6 cm<sup>2</sup>. The aortic valve maximum gradient is 38 mmHg.

**Pulmonary Valve:** The estimated peak systolic PA/RV pressure is 44 mmHg.

**Tricuspid Valve:** The tricuspid valve morphology and function is normal.

**Left Atrium:** The left atrium is mildly enlarged.

**Right Ventricle:** The right ventricular chamber size, wall thickness and contractility are normal.

**Right Atrium:** The right atrium is normal in size.

**Pulmonary Artery Pressure:** Pulmonary hypertension is present. Tricuspid regurgitation predicts the pulmonary arterial systolic pressure to be 36 mmHg plus the central venous pressure.

**Aorta:** The aorta is normal in caliber.

**Pericardium:** The pericardium appears normal without evidence of significant pericardial effusion.

**Measurements**

M-mode/2D			Diastolic Parameters	
Aorta Root Diameter	3.1	cm	-- Mitral Inflow --	
Left Atrium Diameter	4.1	cm	E Wave	cm/s
LVOT Diameter (Systole)		mm	A Wave	cm/s
Septal Wall Thickness	1.3	cm	Decel Time	msec
Posterior Wall Thickness	1.1	cm	IVRT	msec
LVEDD	5.8	cm	-- Tissue Doppler --	
LVESD	4.8	cm	Septal E Wave	cm/s
LV Ejection Fraction	30%		Lateral E Wave	cm/s
Fractional Shortening	17%			
LVOT TVI		cm	-- Pulmonary Vein Inflow --	
<b>Hemodynamics</b>			A. Wave Reversal	cm/s
LV Stroke Volume		mL	S : D Ratio	
RV Stroke Volume		mL		
Qp/Qs				

**Patient Name:** Wilson Jackson  
**Procedure Date:** 02/06/2011 14:05:00  
**Date of Birth:** 12/19/1962

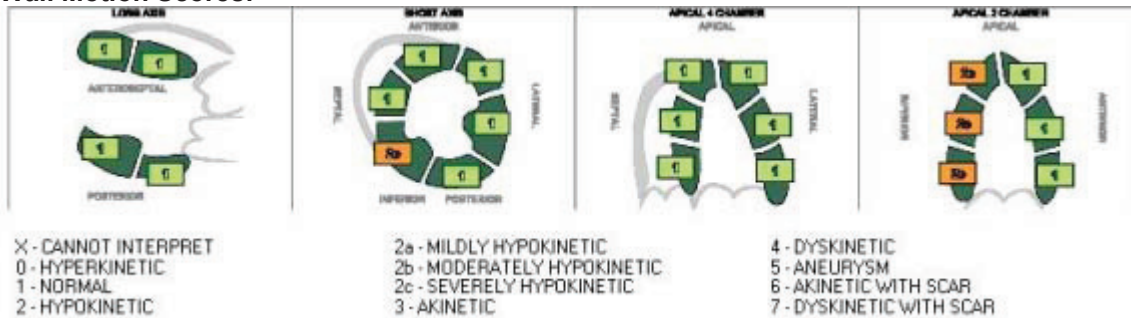
**Gender:** M  
**MRN:** 562525256  
**Age:** 48

Position	Regurgitation	Stenosis	Peak Gr mmHg	Mean G mmHg	TVI	Valve Ar cm2
Aortic Valve	mild	mild	38 mmHg	mmHg		1.6 cm2
Mitral Valve			mmHg	mmHg		cm2
Tricuspid Valve			mmHg	mmHg		cm2
Pulmonic Valve			mmHg	mmHg		cm2
Heart Rate		76	BPM			
Blood Pressure		122/78	mmHg			
Doppler Calc AoV Area		1.6	cm2			

**Impression:**

The left ventricle is moderately dilated and mildly hypertrophied and has an EF of 30%.  
 The mid, basilar and apical segments of the inferior wall are severely hypokinetic.  
 Mild aortic valve stenosis.  
 Mitral annular calcification with no thickening of the mitral leaflets. Mild mitral regurgitation.  
 Pulmonary hypertension is present.

**Wall Motion Scores:**



**CPT Code(s):**

93306, Echocardiography, transthoracic, real-time with image documentation (2D), includes M-mode recording, when performed, complete, with spectral Doppler echocardiography, and with color flow Doppler echocardiography

**ICD Code(s):**

428.0, Congestive heart failure, unspecified  
 429.3, Cardiomegaly  
 793.2, Nonspecific abnormal findings on radiological and other examination of other intrathoracic organs  
 396.2, Mitral valve insufficiency and aortic valve stenosis  
 424.0, Mitral valve disorders  
 416.8, Other chronic pulmonary heart diseases

CPT Copyright 2010 American Medical Association. All Rights Reserved.

**E-signed by Tyrone X Smith, MD**

Electronically signed by: Tyrone X. Smith MD  
 Signed Date: 2/6/2011 14:35:48  
 Number of Addenda: 0  
 Note generated on: 2/6/2011 14:35:48