

■ ProVation® MD – Sample ERCP Note

Patient Name: Wilson Jackson
Gender: M
Procedure Date: 07/06/2007
MRN: 562525256
Date of Birth: 19/12/1963

Admit Type: Inpatient
Account #: 998877456
Note Status: Complete
Consulting MD: Thomas C. Paine MD
Age: 43

Procedure: ERCP

Indications: Abdominal pain of suspected biliary or pancreatic origin, Suspected bile duct stone(s)

Providers: Thomas C. Paine, MD, Robert J. Stiles, MD (1st Assisting Doctor)

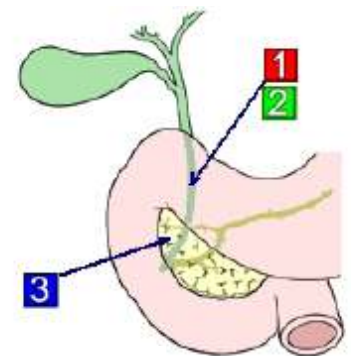
Referring MD: Tyrone X. Smith, MD

Medicines: Midazolam 2 mg IV, Fentanyl 100 micrograms IV

Complications: No immediate complications and no estimated blood loss

Procedure:

The risks and benefits of the procedure and the sedation options and risks were discussed with the patient. All questions were answered and informed consent was obtained. Patient identification and proposed procedure were verified by the physician and the nurse in the endoscopy suite at 07:45 AM. Mental Status Examination: normal. Airway Examination: normal oropharyngeal airway and neck mobility. Respiratory Examination: clear to auscultation. CV Examination: normal. Prophylactic Antibiotics: The patient requires prophylactic antibiotics due to a prior history of endocarditis and synthetic vascular graft less than 1 year old and for the planned performance of ERCP in obstructed bile duct. ASA Grade Assessment: II - A patient with mild systemic disease. After reviewing the risks and benefits, the patient was deemed in satisfactory condition to undergo the procedure. The anaesthesia plan was to use moderate sedation / analgesia (conscious sedation). After obtaining informed consent, the scope was passed under direct vision. The duodenoscope was introduced through the mouth, and advanced to the duodenum and used to inject contrast into the bile duct. The ERCP was somewhat difficult due to challenging cannulation because of peridiverticular papilla. The patient tolerated the procedure well.



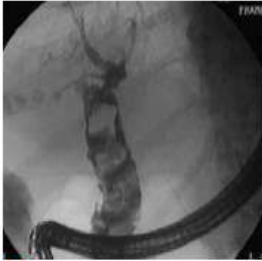The Biliary Tree

The scout film was normal. The oesophagus was successfully intubated under direct vision. The scope was advanced to a normal major papilla in the descending duodenum without detailed examination of the pharynx, larynx and associated structures, and upper GI tract. The upper GI tract was grossly normal. The bile duct was deeply cannulated with the short-nosed traction sphincterotome. Contrast was injected. I personally interpreted the bile duct images. There was brisk flow of contrast through the ducts. Image quality was adequate. Contrast extended to the cystic duct. Opacification of the entire biliary tree was successful. The lower third of the main bile duct contained multiple stones, the largest of which was 6 mm in diameter. The lower third of the main bile duct was diffusely dilated. The largest diameter was 12 mm. A cholecystectomy had been performed. A straight Roadrunner wire was passed into the biliary tree. A 10 mm biliary sphincterotomy was made with a monofilament short-tip traction sphincterotome using ERBE electrocautery. There was no post-sphincterotomy bleeding. The biliary tree was swept with a balloon starting at the bifurcation. All stones were removed and no stones were left.

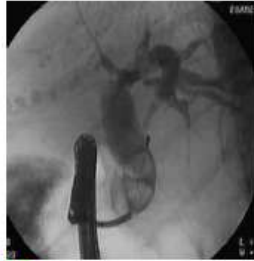Patient Name: Wilson Jackson
Gender: M
Procedure Date: 06/07/2007
MRN: 562525256
Date of Birth: 19/12/1963
Procedure Date: 06/07/2007

Admit Type: Inpatient
Account #: 998877456215
Note Status: Complete
Attending MD: Thomas C. Paine MD
Age: 43

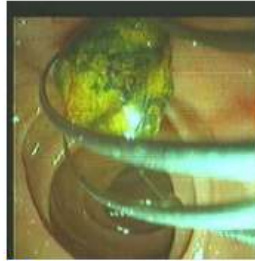
Add'l Images:



1 Main duct. Multiple biliary stones.



2 Extraction of CBD stones.



3 2nd portion of duodenum. Extracted stone.

Impression:

- Choledocholithiasis with an obstruction was found. Complete removal was accomplished by biliary sphincterotomy and balloon extraction.

Recommendation:

- Return patient to hospital ward for ongoing care.
- NBM today.
- Check amylase in the morning.
- Watch for pancreatitis, bleeding, perforation, and cholangitis.
- The findings and recommendations were discussed with the referring physician.

E-signed by Thomas C. Paine, MD

Thomas C. Paine, MD
Signed Date: 06/07/2007 16:08:07
Number of Addenda:
This report has been signed electronically.
Note initiated on 06/07/2007 07:53:55

E-signed by Robert J. Stiles, MD

Robert J. Stiles, MD