

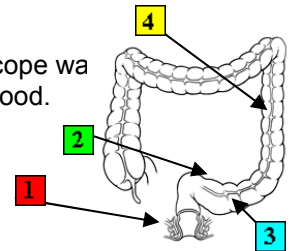
ProVation® MD – Sample GI Note

Patient Name: Mabel Davis
Procedure Date: 01/02/2009
Date of Birth: 01/01/1939

Gender: F
MRN: 084985
Age: 67

Procedure: Colonoscopy
Indications: Hematochezia, Personal history of colonic polyps
Providers: Dr. John H. White FRACP, Dr. Kevin P. Taylor (Anaesthetist)
Referring MD: Dr. William Jones
Medications: Midazolam 2 mg IV, Fentanyl 100 mcg IV
Procedure:

After informed consent was obtained, the scope was passed under direct vision. The colonoscope was introduced through the anus and advanced to the terminal ileum. The quality of the prep was good. prep was adequate to identify polyps >5 mm in size. The patient tolerated the procedure well. Scope withdrawal time was 12 minutes.



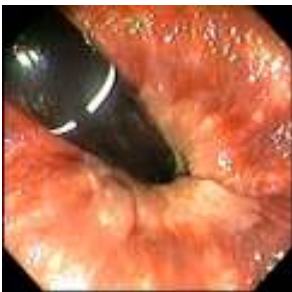Findings:

A sessile, non-bleeding polyp was found in the rectum. The polyp was 9 mm in size. Polypectomy was performed with a hot forceps. Resection and retrieval were complete. Estimated blood loss was minimal.

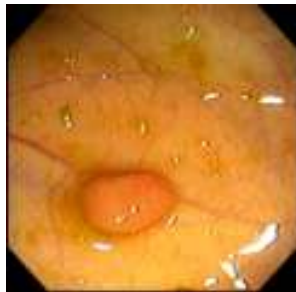One pedunculated, non-bleeding polyp was found in the sigmoid colon. The polyp was 17 mm in size. Polypectomy was performed with a saline-injection lift using the hot snare. Resection and retrieval were complete.

Multiple large-mouthed diverticula were found in the descending colon.

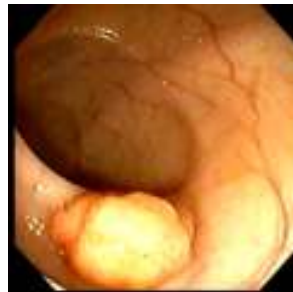Internal, non-bleeding, prolapsed with spontaneous reduction (grade II) haemorrhoids were found on retroflexion.



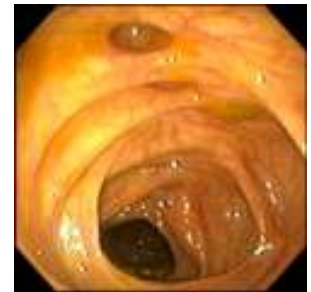1 Rectum/Haemorrhoids



2 Rectum/Polyp



3 Sigmoid Colon/Polyp



4 Descending Colon/Diverticula

Impression:

- One 9 mm benign appearing polyp in the rectum. Resected and retrieved.
- One 17 mm polyp in the sigmoid colon. Resected and retrieved.
- Diverticulosis.
- Internal haemorrhoids were found.

Patient Name: Mabel Davis
Procedure Date: 01/02/2009
Date of Birth: 01/01/1939

Gender: F
MRN: 084985
Age: 67

Recommendation:

- The patient was observed post-procedure, until all discharge criteria were met.
- High fibre diet.
- Await pathology results.
- Repeat colonoscopy in 3 - 5 years for surveillance based on pathology results.
- Return to General Practitioner in 3 weeks.
- The findings and recommendations were discussed with the patient.

E-signed by Dr. John H. White

Dr. John H. White

Signed Date: 01/02/2009 16:08:07

Number of Addenda: 0

This report has been signed electronically.

www.provationmedical.com

Printed May 2009.