

# ProVation<sup>®</sup> MD

Leading the way in procedure documentation and coding

## Pulmonology

Inbound Demographic

Inbound Scheduling

Comprehensive Medical Content

Outbound Results

CPT/ICD Codes/CCI Edits Driven By Medical Content

Outbound Charges/Codes

Medical and Imaging Device Interface

**General Hospital - Sample Bronchoscopy Note**

**Procedure Date:** 04/22/2018 11:05 am  
**Admit Type:** Outpatient  
**New Status:** Finalized

**Procedure:** 31231, Bronchoscopy, right or flexible, with or without fluoroscopic guidance, with bronchial or endobronchial biopsy, single or multiple sites

**ICD Codes:**  
 J20.9, Bronchitis, unspecified  
 J31.9, Chronic obstructive pulmonary disease, unspecified

**Outbound Results:**  
 The nasopharyngolarynx appears normal. The larynx appears normal. The vocal cords are normal and move normally with phonation and breathing. The laryngeal space is normal. The trachea is of normal caliber. The carina is sharp. The bronchovascular roots of the right lung are diminished in at least the first subsegmental level. Bronchovascular markings and branching in the right lung are normal. There are no endobronchial lesions, and no secretions.

**Procedure Date:** 04/22/2018 11:05 am  
**Admit Type:** Outpatient  
**New Status:** Finalized

**CPT Codes:**  
 31231, Bronchoscopy, right or flexible, with or without fluoroscopic guidance, with bronchial or endobronchial biopsy, single or multiple sites

**ICD Codes:**  
 J20.9, Bronchitis, unspecified  
 J31.9, Chronic obstructive pulmonary disease, unspecified

**Procedure Description:**  
 A bronchoscopy was performed. The procedure was unremarkable. The bronchovascular markings and branching in the right lung are normal. There are no endobronchial lesions, and no secretions.

**Imaging:**  
 A bronchogram was performed. The bronchovascular markings and branching in the right lung are normal. There are no endobronchial lesions, and no secretions.

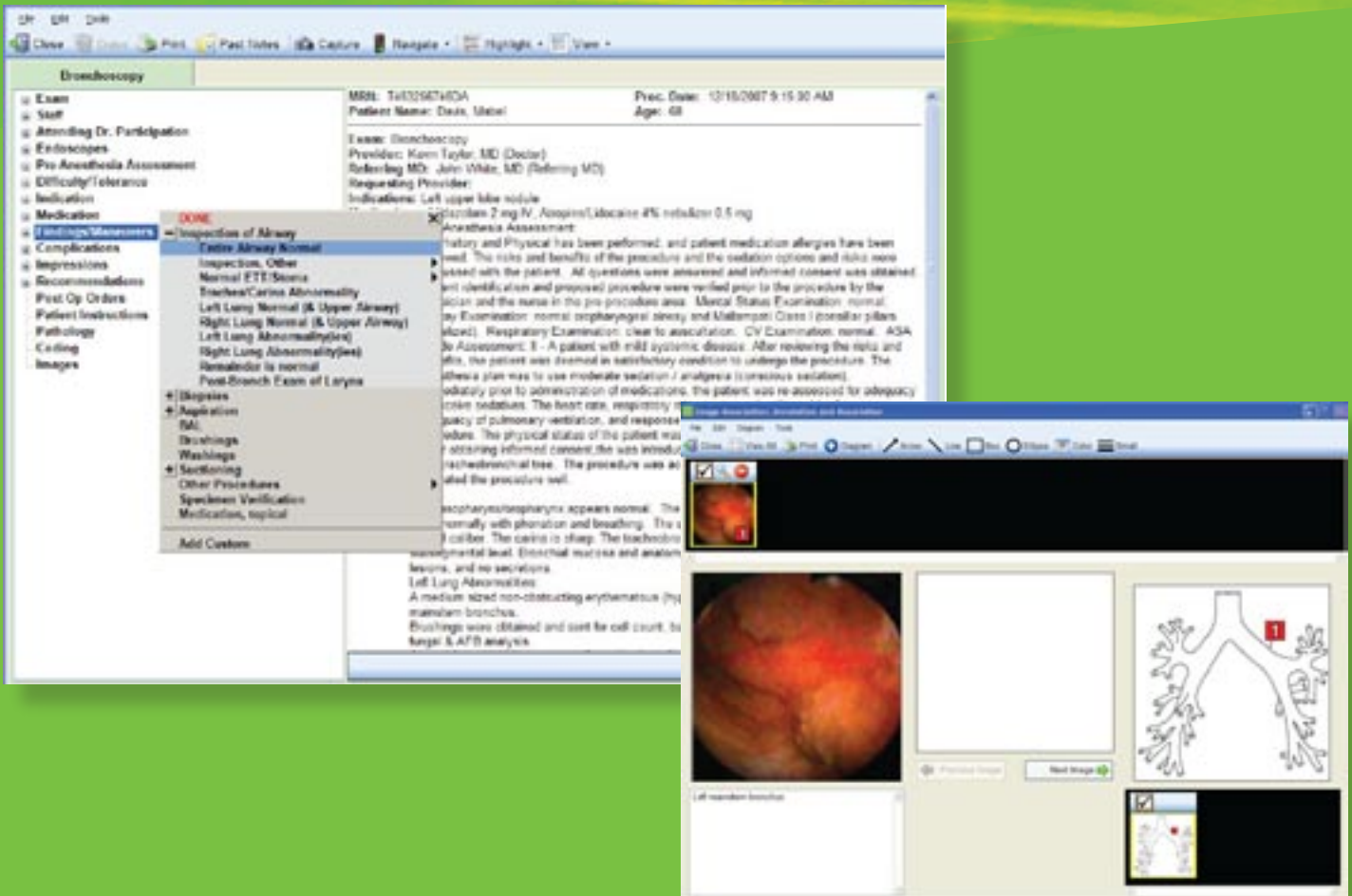
**Outbound Results:**  
 The nasopharyngolarynx appears normal. The larynx appears normal. The vocal cords are normal and move normally with phonation and breathing. The laryngeal space is normal. The trachea is of normal caliber. The carina is sharp. The bronchovascular roots of the right lung are diminished in at least the first subsegmental level. Bronchovascular markings and branching in the right lung are normal. There are no endobronchial lesions, and no secretions.

### RICH MEDICAL CONTENT THAT INCLUDES:

- Bronchoscopy
  - Endobronchial Biopsy
  - Transbronchial Biopsy
  - BAL
  - Balloon Occlusion
  - Balloon Dilation
  - Brachytherapy
- Bronchography
  - Cryotherapy
  - Cautery
  - Excision
  - Foreign Body Removal
  - Laser Treatment
  - LIFE
- Stent Placement
  - Endo Bronchial Ultra Sound
  - Flexible Fiberoptic Laryngoscopy
  - Chest Tube Placement
  - Thoracentesis

Mapped to 40 CPT and 350 ICD-9 Codes

# Pulmonology



- Creates a single, complete and easily retrieved electronic note for each procedure
- Comprehensive medical content built by ProVation's in-house physician team
- Instantly and automatically prepares Patient Letters, Referring MD Letters, CC: Letters, Post-Op Orders, Patient Instructions, and Referring MDs and more
- Interfaces with scopes and other image capture equipment for instant inclusion of images in the procedure note
- Based on physician entries, CPT-4 and ICD-9 codes and CCI edits are automatically generated